

CLINICAL CASE REPORT

Massive pericardial effusion without cardiac tamponade due to subclinical hypothyroidism (Hashimoto's disease)

AUTHORS



Panteleimon E Papakonstantinou¹ MD, Internal Medicine Resident *, pantelisapakon@gmail.com

Nikolaos Gourniezakis² MD, Consultant Internal Medicine

Christos Skiadas³ MD, Consultant Radiology

Alexandros Patrianakos⁴ MD, PhD, Consultant Cardiology

Achilleas Gikas⁵ MD, PhD, Professor of Internal Medicine, Head of the Internal Medicine Department

CORRESPONDENCE

*Dr Panteleimon E Papakonstantinou pantelisapakon@gmail.com

AFFILIATIONS

^{1, 2, 5} Department of Internal Medicine, University Hospital of Heraklion, Heraklion, Crete, Greece

³ Department of Radiology, University Hospital of Heraklion, Heraklion, Crete, Greece

⁴ Department of Cardiology, University Hospital of Heraklion, Heraklion, Crete, Greece

PUBLISHED

20 May 2018 Volume 18 Issue 2

HISTORY

RECEIVED: 18 February 2017

REVISED: 1 July 2017

ACCEPTED: 21 September 2017

CITATION

Papakonstantinou PE, Gourniezakis N, Skiadas C, Patrianakos A, Gikas A. Massive pericardial effusion without cardiac tamponade due to subclinical hypothyroidism (Hashimoto's disease). *Rural and Remote Health* 2018; **18**: 4384. <https://doi.org/10.22605/RRH4384>

© Panteleimon E Papakonstantinou, Nikolaos Gourniezakis, Christos Skiadas, Alexandros Patrianakos, Achilleas Gikas 2018 A licence to publish this material has been given to James Cook University, jcu.edu.au

ABSTRACT:

Context: Hypothyroidism is a significant cause of pericardial effusion. However, large pericardial effusions due to hypothyroidism are extremely rare. Hormone replacement therapy is the cornerstone of treatment for hypothyroidism and regular follow-up of patients after initiation of the therapy is indicated. Herein, the case of a 70-year-old woman with

a massive pericardial effusion due to Hashimoto's disease is presented.

Issues: A 70-year-old female from a rural village on the island of Crete, Greece, was admitted to our hospital due to a urinary tract infection. She was under hormone replacement therapy with levothyroxine 100 µg once a day for Hashimoto's disease. Two years previously, the patient had had an episode of pericarditis due to hypothyroidism and had undergone a computed tomography-guided pericardiocentesis. The patient did not have regular follow-up and did not take the hormone replacement therapy properly. On admission, the patient's chest X-ray incidentally showed a possible pericardial effusion. The patient was referred for echocardiography, which revealed a massive pericardial effusion. Beck's triad was absent. Thyroid hormones were consistent with subclinical hypothyroidism: thyroid-stimulating hormone (TSH) 30.25 mIU/mL (normal limits: 0.25–3.43); free thyroxine 4 0.81 ng/dL (normal limits: 0.7–1.94). The patient had a score of 5 on the scale outlined by the European Society of Cardiology (ESC) position statement on triage strategy for cardiac tamponade and, despite the absence of cardiac tamponade, a pericardiocentesis was performed after 48 hours. The patient was treated with 125 µg levothyroxine orally once daily.

Lessons learned: This was a rare case of an elderly female patient from a rural village with chronic massive pericardial effusion due to subclinical hypothyroidism without cardiac tamponade. Hypothyroidism should be included in the differential diagnosis of pericardial effusion, especially in a case of unexplained pericardial fluid. Initiation of hormone replacement therapy should be personalised in elderly patients. TSH levels >10 mU/L usually require therapy with levothyroxine in order to prevent adverse events. Rural patients usually do not have regular follow-up after the initiation of hormone replacement therapy. Pericardial effusions due to hypothyroidism grow slowly and subclinical hypothyroidism rarely shows signs and symptoms and can be underdiagnosed. The ESC position statement on triage strategy for pericardial diseases is a valuable clinical tool to estimate the necessity for pericardial drainage in such cases.

KEYWORDS:

cardiac tamponade, Hashimoto's disease, pericardial effusion, subclinical hypothyroidism.

FULL ARTICLE:

Context

Hypothyroidism is a common endocrine disorder and a significant cause of pericardial effusion¹. Hormone replacement therapy is the cornerstone of treatment for hypothyroidism and, after initiation of therapy, regular follow-up of the patients is indicated. Compliance with hormone therapy is also an important issue, especially for patients in rural and remote areas. Subclinical hypothyroidism is a frequent entity in daily clinical practice and is defined by elevated levels of thyroid-stimulating hormone (TSH) with normal levels of free thyroid hormones in serum². However, large pericardial effusions due to hypothyroidism are rare^{1,3} and their clinical management is always challenging. Herein, the case of a 70-year-old rural woman with a massive pericardial effusion due to Hashimoto's disease is presented. The patient provided written consent to appear in the article.

Issues

Case report

A 70-year-old female from a rural village in Crete, Greece, was admitted to our hospital with a urinary tract infection. Her medical history included arterial hypertension, dementia and hypothyroidism due to Hashimoto's disease. She was under replacement therapy with levothyroxine 100 µg once a day. She had suffered four ischaemic strokes during the past 20 years and was under treatment with acetylsalicylic acid 160 mg OD (once daily). She had a homozygous methylenetetrahydrofolate reductase (MTHFR) C677T mutation with elevated homocysteine levels. Two years previously, the patient had had an episode of pericarditis due to hypothyroidism and had undergone a computed tomography (CT)-guided pericardiocentesis. The patient did not have regular follow-up after the procedure and did not take the hormone replacement therapy properly.

On admission, the patient was haemodynamically stable without fever, or chest pain. Laboratory tests showed high white blood cells (WBC) of 18.000 K/ μ L, an elevated level of C-reactive protein (CRP) of 5.4 mg/dL (normal limit: 0.08–0.8 mg/dL) and erythrocyte sedimentation rate of 3 mm in the first hour. The chest X-ray (Fig1a) showed a possible pericardial effusion, which was an incidental finding. The patient was referred to emergency bedside echocardiography, which revealed a massive pericardial effusion without evidence of cardiac tamponade, normal left ventricular systolic function and normal wall thickness with ejection fraction of 60%. Beck's triad was absent. The electrocardiograph (ECG) is shown in Figure 1b. There was no dynamic change from the patient's baseline ECG. During hospitalisation, the patient was under antibiotic treatment with levofloxacin, while for the possible pericarditis she was under treatment with ibuprofen 600 mg every 8 hours and colchicine 0.5 mg OD according to the European Society of Cardiology (ESC) guidelines⁴. On the third day, she presented with acute kidney failure, which was considered drug-induced and ibuprofen and colchicine were replaced with prednisone 30 mg intravenously OD (0.50 mg/kg/day)⁴. WBC and CRP decreased gradually and were within the normal limits on the sixth day of hospitalisation. Virological blood tests for herpesviruses (cytomegalovirus, Epstein–Barr virus), enteroviruses (echoviruses, coxsackieviruses), adenoviruses, parvovirus and human immunodeficiency virus were negative. Mantoux tuberculin skin test for tuberculosis was also negative. Rheumatoid factor, anti-nuclear antibodies and anti-neutrophil cytoplasmic antibodies were negative. Thyroid hormones were consistent with subclinical hypothyroidism: TSH 30.25 mIU/L (normal limits: 0.25–3.43); free thyroxin 4 0.81 ng/dL (normal limits: 0.7–1.94). Thyroid antibodies were: anti-thyroid peroxidase antibody >1000 IU/mL (normal limit: <5.61) and anti-thyroglobulin 2.79 IU/mL (normal limit: <4.11).

A new echocardiograph and chest CT (Fig2a,b) were performed, revealing a massive pericardial effusion with no evidence of aortic dissection or neoplastic pericardial involvement and without echocardiographic findings of cardiac tamponade. According to the ESC position statement on triage strategy for pericardial diseases⁵, the patient had a score of 5 and, despite the absence of cardiac tamponade, a pericardiocentesis was performed after 48 hours. During the procedure, 1070 mL of pericardial fluid was drained and analysis showed exudate. Cytological examination was negative for malignancy. Pericardial fluid culture was negative. Consequently, subclinical hypothyroidism was considered the cause of the pericardial effusion and the patient was treated with 125 μ g levothyroxine orally OD.

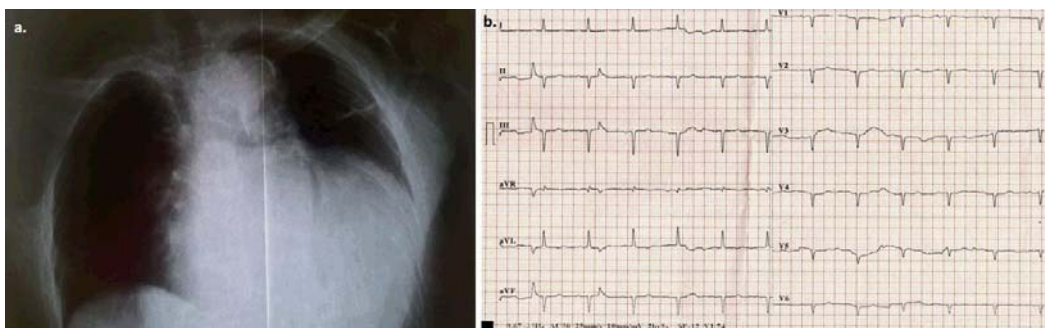


Figure 1: a. Front chest X-ray demonstrates marked enlargement of the cardiac outline. b. Electrocardiograph (ECG) on admission. Sinus rhythm (~85 bpm), left axis deviation, Q-waves in leads II, III, and poor progression of R-waves in the precordial leads, flattened T-waves in all leads, low QRS voltage in all precordial leads. There was no dynamic change from the patient's baseline ECG.

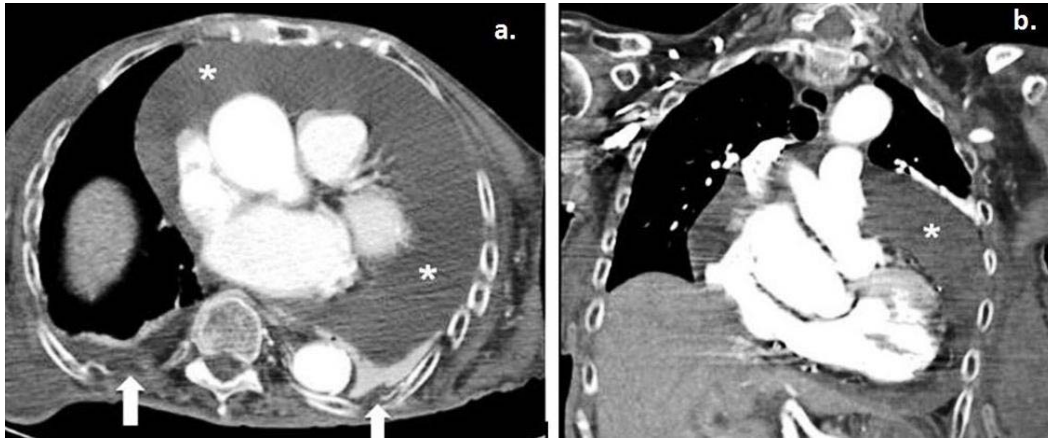


Figure 2: a. Axial contrast-enhanced computed tomography and coronal maximum intensity projection–reconstruction during the patient’s hospitalisation revealed a large global pericardial effusion (*). b. Small bilateral pleural effusions are also noted (white arrows).

Lessons learned

Massive pericardial effusion is always an important clinical finding, even if incidental and, when it occurs, cardiac tamponade should be excluded and a diagnostic workup should be performed⁶. Hypothyroidism should always be included in the differential diagnosis in cases of an unexplained massive pericardial effusion^{2,3,5,7}. Once the diagnosis has been established and treatment has started, pericardial fluid regresses slowly and can be gone several months after the initiation of hormone replacement therapy³.

Pericardial effusion due to hypothyroidism rarely causes cardiac tamponade⁷ and it tends to be chronic because it progresses slowly. Whenever a pericardial emission progresses slowly, the pericardial sac has enough time to stretch and can subsequently contain a large amount of pericardial fluid without a significant rise in intrapericardial pressure⁸. In the absence of ongoing inflammation treatment for chronic idiopathic effusions of any size with aspirin, non-steroidal anti-inflammatory drugs, colchicine and/or steroids are not effective⁶. However, in the present case, it was difficult to distinguish the origin of the elevated inflammation markers (WBC, CRP) and it was initially decided to treat both the urinary tract infection and the possible pericarditis.

A scoring system was introduced by Halpern et al⁹ to guide the decision for pericardial drainage based on clinical factors, the echocardiographic assessment of haemodynamics and the size of the pericardial effusion. The ESC Working Group on Myocardial and Pericardial Diseases proposed a new stepwise scoring system for the triage of patients requiring pericardiocentesis⁵. In the present patient, there was no clinical or echocardiographic sign of cardiac tamponade. However, due to the large pericardial effusion, the decision to perform a late echo-guided pericardiocentesis was made.

The incidence of subclinical hypothyroidism varies between 4 and 10% depending on the age, gender and population studied^{10,11}. It is more frequent in iodine-sufficient regions and in individuals of white, Caucasian origin^{11,12}. The consequences of subclinical hypothyroidism are variable and may depend on the degree of elevation of TSH along with the duration of the disorder. Subclinical hypothyroidism is generally classified according to the elevation in TSH: a more severely increased TSH value (>10 mIU/L) as in the present case or mildly increased TSH levels (4.0–10.0 mIU/L), which accounts for around 90% of cases^{11,12}. However, there has been a widening of the reference range for TSH in elderly people, and a mild TSH elevation (4.0–7.0 mIU/L) in patients >80 years should be considered a physiological adaptation to aging^{11,13}. Furthermore, an initially raised TSH and free thyroxine 4 within normal range should be followed-up with a repeat measurement after a 2–3 month interval¹¹. Consequently, the management of this metabolic disorder, especially in elderly patients in the rural health setting, is challenging, because the primary care physician has to decide whether the patient should initiate treatment with levothyroxine.

In elderly individuals, initiation of treatment for subclinical hypothyroidism should be personalised and closely monitored¹¹. A wait-and-see strategy is preferred, avoiding hormone replacement therapy in patients >80–85 years old with TSH ≤10 mIU/L¹¹. In patients between 60 and 70 years old, the decision of when to initiate treatment should be based on the evaluation of several factors, including frailty, comorbidities and degree of TSH elevation. For patients of these ages, a small dose of levothyroxine should be initiated (25 or 50 µg daily), and the dose should be increased by 25 µg/day every 14–21 days until a full replacement dose is reached¹¹. TSH level should be re-assessed 2 months after the initiation of treatment, and dose adjustments should be made accordingly. According to the European Thyroid Association (ETA) Guidelines for Subclinical Hypothyroidism¹¹, the aim for most adult patients is a stable TSH in the lower half of the reference range (0.4–2.5 mIU/L), although for patients >70–75 years, a higher target for TSH (around 1–5 mIU/L) is also acceptable. Once the patients achieve desirable levels of serum TSH, TSH should be monitored annually at least.

Data on the use of the hormone replacement therapy in rural areas are sparse in the literature and the compliance of the patients in such areas has not been well established. The study of rural and remote areas is interesting and challenging because rural and remote patients usually have special cultural conditions in combination with limited access to healthcare services. In the present case, the patient lived in a remote and rural village on the island of Crete with limited access to primary care services. Consequently, she did not have regular follow-up and hypothyroidism was not treated properly.

In conclusion, this was a rare case of a patient with chronic massive pericardial effusion due to subclinical hypothyroidism without cardiac tamponade. Hypothyroidism should be included in the differential diagnosis of pericardial effusion, especially in cases of unexplained pericardial fluid. Pericardial effusions due to hypothyroidism grow slowly and subclinical hypothyroidism rarely show signs and symptoms and can be underdiagnosed. Initiation of hormone replacement therapy should be personalised in elderly patients. However, TSH levels >10 mIU/L usually require therapy with levothyroxine in order to prevent the adverse events due to this 'silent' metabolic disorder. Patients who live in rural and remote places usually do not have regular follow-up of systemic diseases such as hypothyroidism. The ESC position statement on triage strategy for pericardial diseases⁵ is a valuable clinical tool to estimate the necessity for pericardial drainage in such cases.

REFERENCES:

- 1 Purkait R, Prasad A, Bhadra R, Basu A. Massive pericardial effusion as the only manifestation of primary hypothyroidism. *Journal of Cardiovascular Disease Research* 2013; **4**: 248-250. <https://doi.org/10.1016/j.jcdr.2014.01.001> PMID:24653591
- 2 Dattilo G, Crosca S, Tavella S, Marte F, Patane S. Pericardial effusion associated with subclinical hypothyroidism. *International Journal of Cardiology* 2011; **153**: e47-50. <https://doi.org/10.1016/j.ijcard.2009.03.090> PMID:19376599
- 3 Omura Y, Ugi S, Sugimoto T, Nishio Y, Maegawa H, Kashiwagi A. Massive pericardial effusion secondary to Hashimoto's disease. *European Journal of Internal Medicine* 2007; **18**: 438-440. <https://doi.org/10.1016/j.ejim.2007.05.001> PMID:17693236
- 4 Adler Y, Charron P, Imazio M, Badano L, Baron-Esquivias G, Bogaert J, et al. 2015 ESC Guidelines for the diagnosis and management of pericardial diseases: The Task Force for the Diagnosis and Management of Pericardial Diseases of the European Society of Cardiology (ESC) Endorsed by: The European Association for Cardio-Thoracic Surgery (EACTS). *European Heart Journal* 2015; **36**: 2921-2964. <https://doi.org/10.1093/eurheartj/ehv318> PMID:26320112
- 5 Ristic AD, Imazio M, Adler Y, Anastasakis A, Badano LP, Brucato A, et al. Triage strategy for urgent management of cardiac tamponade: a position statement of the European Society of Cardiology Working Group on Myocardial and Pericardial Diseases. *European Heart Journal* 2014; **35**: 2279-2284. <https://doi.org/10.1093/eurheartj/ehu217> PMID:25002749

- 6 Imazio M, Spodick DH, Brucato A, Trincherio R, Adler Y. Controversial issues in the management of pericardial diseases. *Circulation* 2010; **121**: 916-928. <https://doi.org/10.1161/CIRCULATIONAHA.108.844753> PMID:20177006
- 7 Gupta R, Munyak J, Haydock T, Gernsheimer J. Hypothyroidism presenting as acute cardiac tamponade with viral pericarditis. *The American Journal of Emergency Medicine* 1999; **17**: 176-178. [https://doi.org/10.1016/S0735-6757\(99\)90056-6](https://doi.org/10.1016/S0735-6757(99)90056-6)
- 8 Fadel BM, Galzerano D, Pergola V, Di Salvo G. Massive pericardial effusion without cardiac tamponade. *European Heart Journal* 2016; **37**: 2612. <https://doi.org/10.1093/eurheartj/ehw076> PMID:26941205
- 9 Halpern DG, Argulian E, Briasoulis A, Chaudhry F, Aziz EF, Herzog E. A novel pericardial effusion scoring index to guide decision for drainage. *Critical Pathways in Cardiology* 2012; **11**: 85-88. <https://doi.org/10.1097/HPC.0b013e318254a5ca> PMID:22595820
- 10 Canaris GJ, Manowitz NR, Mayor G, Ridgway EC. The Colorado thyroid disease prevalence study. *Archives of Internal Medicine* 2000; **160**: 526-534. <https://doi.org/10.1001/archinte.160.4.526> PMID:10695693
- 11 Pearce SH, Brabant G, Duntas LH, Monzani F, Peeters RP, Razvi S, et al. 2013 ETA Guideline: Management of Subclinical Hypothyroidism. *European Thyroid Journal* 2013; **2**: 215-228. <https://doi.org/10.1159/000356507> PMID:24783053
- 12 Somwaru LL, Rariy CM, Arnold AM, Cappola AR. The natural history of subclinical hypothyroidism in the elderly: the Cardiovascular Health Study. *The Journal of Clinical Endocrinology and Metabolism* 2012; **97**: 1962-1969. <https://doi.org/10.1210/jc.2011-3047> PMID:22438233
- 13 Surks MI, Hollowell JG. Age-specific distribution of serum thyrotropin and antithyroid antibodies in the US population: implications for the prevalence of subclinical hypothyroidism. *The Journal of Clinical Endocrinology and Metabolism* 2007; **92**: 4575-4582. <https://doi.org/10.1210/jc.2007-1499> PMID:17911171

This PDF has been produced for your convenience. Always refer to the live site <https://www.rrh.org.au/journal/article/4384> for the Version of Record.