

LETTER TO THE EDITOR

Nicorandil infusion during inter-hospital transfer of patients with acute coronary syndrome - What can we do in a rural area of Japan?

Y Nagayoshi¹, Y Kai², S Yumoto³, K Sakaguchi³, C Shudo³, S Takino³, M Hashiyama³, H Kawano²,
Y Kuroda⁴, H Ogawa²

¹National Health Insurance, Aso Central Hospital; Department of Cerebrovascular and Acute Coronary Syndrome, Graduate School of Medical Sciences, Kumamoto University, Aso City, Japan

²Department of Cerebrovascular and Acute Coronary Syndrome, Graduate School of Medical Sciences, Kumamoto University, Kumamoto City, Japan.

³National Health Insurance, Aso Central Hospital, Aso City, Japan.

⁴Department of Community Medicine, Kumamoto University, Kumamoto City, Japan

Submitted: 2 May 2013; Accepted: 11 June 2013; Published: 10 December 2013

Nagayoshi Y, Kai Y, Yumoto S, Sakaguchi K, Shudo C, Takino S, Hashiyama M, Kawano H, Kuroda Y, Ogawa H

Nicorandil infusion during inter-hospital transfer of patients with acute coronary syndrome - What can we do in a rural area of Japan?

Rural and Remote Health 13: 2652. (Online) 2013

Available: <http://www.rrh.org.au>

Dear Editor

Timely coronary reperfusion is the most effective therapy for acute coronary syndrome (ACS). For residents living in rural areas, it is a critical problem that most local hospitals do not have acute percutaneous coronary intervention (PCI) capability. Treatment delays due to patient transport have a deleterious effect on infarct size. Thrombolytic therapy is indicated for the patients with ST elevation myocardial

infarction (STEMI)¹. However, thrombolysis is not recommended for patients with non-ST elevation myocardial infarction (NSTEMI) and unstable angina. Antiplatelet therapy with aspirin is usually started, and unfractionated heparin is injected intravenously. Unfortunately, glycoprotein IIb/IIIa inhibitors are not available in Japan.

There have been many reports about early adjunctive pharmacological therapy in myocardial infarction^{2,3}.



Recently, administration of nicorandil, a hybrid of a nitrate and an ATP-sensitive K⁺ channel opener, before PCI, has been shown to improve clinical outcomes⁴. For these reasons, the authors have been trying a nicorandil infusion protocol during inter-hospital transfer.

Geographical location

Aso Central Hospital is located at the foot of Mt Aso. Mt Aso is one of the world's largest volcanic calderas, located about 40 km east of Kumamoto City (Fig1). The circumference of the caldera is estimated to be 120 km. Aso city is located in the center of the caldera of Mt Aso, where approximately 30,000 people live. There is no PCI-capable hospital in the Aso area. The mean time to transfer from Aso City to hospitals in Kumamoto City is 48 minutes.

Treatment protocol

After diagnosis of ACS, 12 mg of nicorandil dissolved in 100 mL of 0.9% saline was administered. First, 6 mg of nicorandil (50 mL) was injected over 5 minutes. The remaining 6 mg was infused during inter-hospital transfer (1 mL/minute). Nicorandil is a vasodilatory drug, which is contraindicated in patients with cardiogenic shock, right ventricular infarction, left ventricular failure with low filling pressure and hypotension. These patients were excluded. The strategy used was approved by the hospital institutional review board for research on human subjects. The physicians obtained informed consent from each patient (ethics approval no. 5).

Between April 2011 and February 2013, 12 patients with ACS underwent adjunctive nicorandil infusion during inter-hospital transfer. Seven patients with NSTEMI/unstable angina were included in this study. No patient died during transport, and adverse effects of nicorandil were not observed. Chest discomforts were reduced by nicorandil infusion in all seven patients. The sum of ST-segment depression >0.5 mm before and after nicorandil infusion (prior to reperfusion therapy) was compared. ST-segment resolution during inter-hospital transfer was observed in five

patients. Recanalization before PCI was confirmed in six patients.

Discussion

In areas with a shortage of physicians, simple treatment is required so that non-cardiologists can transfer ACS patients safely to PCI-capable hospitals. 'Drip and ship' nicorandil infusion during inter-hospital transfer is a simple and safe method. Nicorandil injection improves pulmonary capillary wedge pressure and cardiac index. Improving the haemodynamic state might partially contribute to the relief of chest discomfort. In some patients that received nicorandil infusion, not only relief of chest discomfort but ST resolution was observed, even before reperfusion therapy.

Vasospastic angina plays an important role in the pathogenesis of ACS in Japanese patients⁵. The authors experienced a case of active variant angina refractory to sublingual nitroglycerin. In this case, vasospasm was successfully stabilized by our nicorandil infusion protocol. This method might be useful for these patients.

The number of study patients was too small to draw definitive conclusions. A prospective, population-based study is needed in the future to confirm the safety and usefulness of this method.

The 'drip and ship' method of treating ACS patients is simple, safe and can be used by all physicians. This method might improve the quality of ACS treatment in rural areas.

Acknowledgement

The authors are grateful to Yoshio Yamabe (Yamabe Power Studio) for his important contributions to the map preparation.

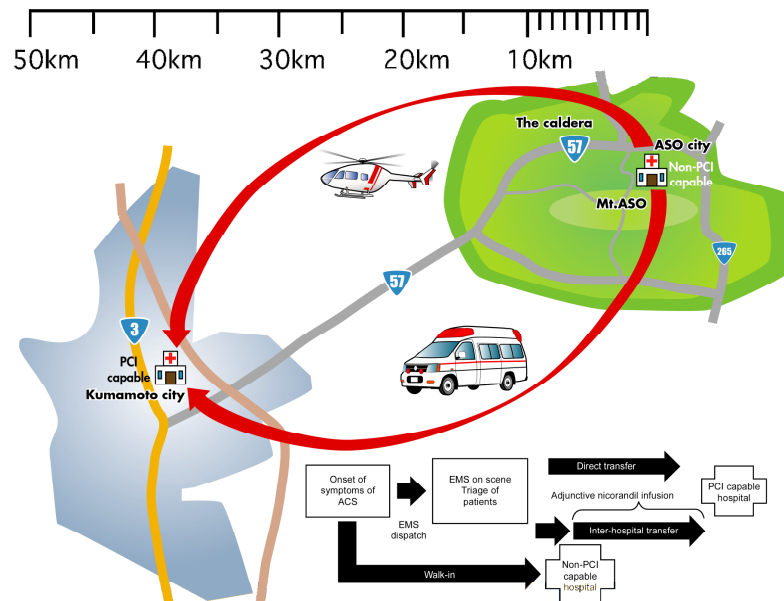


Figure 1: Transfer of patients with ACS from Aso Central Hospital (non-PCI-capable) to Kumamoto University Hospital (PCI-capable). Adjunctive nicorandil infusion protocol was performed if EMS took ACS patients to the non-PCI-capable hospital or the patients directly presented to the non-PCI-capable hospital. ACS, acute coronary syndrome. EMS, emergency medical services. PCI, percutaneous coronary intervention.

Yasuhiro Nagayoshi, MD, PhD
 National Health Insurance Aso Central Hospital, Aso City; Department of Cerebrovascular and Acute Coronary Syndrome, Graduate School of Medical Sciences, Kumamoto University, Kumamoto City, Japan

Yutaka Kai, MD, PhD; Shinya Yumoto, MD; Kazuhisa Sakaguchi, MD; Chiharu Shudo, MD; Shiro Takino, MD; Motohiro Hashiyama, MD, PhD
 National Health Insurance Aso Central Hospital, Aso City, Japan

Hiroaki Kawano, MD, PhD
 Department of Cardiovascular Medicine, Graduate School of Medical Sciences, Kumamoto University, Kumamoto City, Japan

Yutaka Kuroda, MD, PhD
 Department of Community Medicine, Kumamoto University Hospital, Kumamoto City, Japan

Hisao Ogawa, MD, PhD
 Department of Cardiovascular Medicine, Graduate School of Medical Sciences, Kumamoto University, Kumamoto City, Japan

References

1. Krones R, Radford P, Cunningham C, Krones D, Haines HM. Thrombolysis for acute ST elevation myocardial infarction: a pilot study comparing results from GP led small rural health emergency departments with results from a physician led sub-regional emergency department. *Rural and Remote Health* 12: 2013. (Online 2012. Available: www.rrh.org.au (Accessed 1 April 2013).



2. Gerczuk PZ, Kloner RA. An update on cardioprotection: a review of the latest adjunctive therapies to limit myocardial infarction size in clinical trials. *Journal of American College of Cardiology* 2012; **59(11)**: 969-978.

3. Ishii H, Amano T, Matsubara T, Murohara T. Pharmacological intervention for prevention of left ventricular remodeling and improving prognosis in myocardial infarction. *Circulation* 2008; **118(25)**: 2710-2718.

4. Iwakura K, Ito H, Okamura A, Koyama Y, Date M, Higuchi Y et al. Nicorandil treatment in patients with acute myocardial infarction: a meta-analysis. *Circulation Journal* 2009; **73(5)**: 925-931.

5. JCS Joint Working Group. Guidelines for diagnosis and treatment of patients with vasospastic angina (coronary spastic angina) (JCS 2008): digest version. *Circulation Journal* 2010; **74(8)**: 1745-1762.
